第66回 熊本血液形態研究会
症例検討会
症例2

国立病院機構熊本医療センター
米田 祐也

症例

- 【患者】　40歳代　女性
- 【主訴】　発熱 下痢 下血
- 【既往歴】11年前に乳がんの治療歴あり(完全奏功)
  年1回のフォロー中
- 【現病歴】他院にて潰瘍性大腸炎のフォロー中に好中球減少を認め入院。薬剤性の血球減少を考え加療中であったが、血小板減少と末梢血中に芽球を認めたため当院紹介となった。

来院時所見

血算		
WBC	9.68	$\times 10^{9}$/L
RBC	2.68	$\times 10^{12}$/L
Hb	8.6	g/dL
HCT	24.9	%
MCV	92.9	fL
MCH	32.1	pg
MCHC	34.5	g/dL
PLT	21	$\times 10^{9}$/L
Ret	0.5	%

生化学		
TP	6.9	g/dL
Alb	2.8	g/dL
BUN	15	mg/mL
Cre	0.52	mg/mL
UA	3.2	mg/mL
T-Bil	0.2	mg/mL
AST	14	U/L
ALT	15	U/L
LD(IFCC)	811	U/L
CK	11	U/L
Na	135	mEq/L
K	3.7	mEq/L
Cl	97	mEq/L
CRP	10.27	mg/dL

凝固		
PT(秒)	15.7	s
PT(%)	52.7	%
PT(INR)	1.31	
APTT	32.9	s
Fbg	325.4	mg/dL
FDP	18.1	μg/mL
AT	100.6	%
α2-PI	102.8	%

末梢血液像

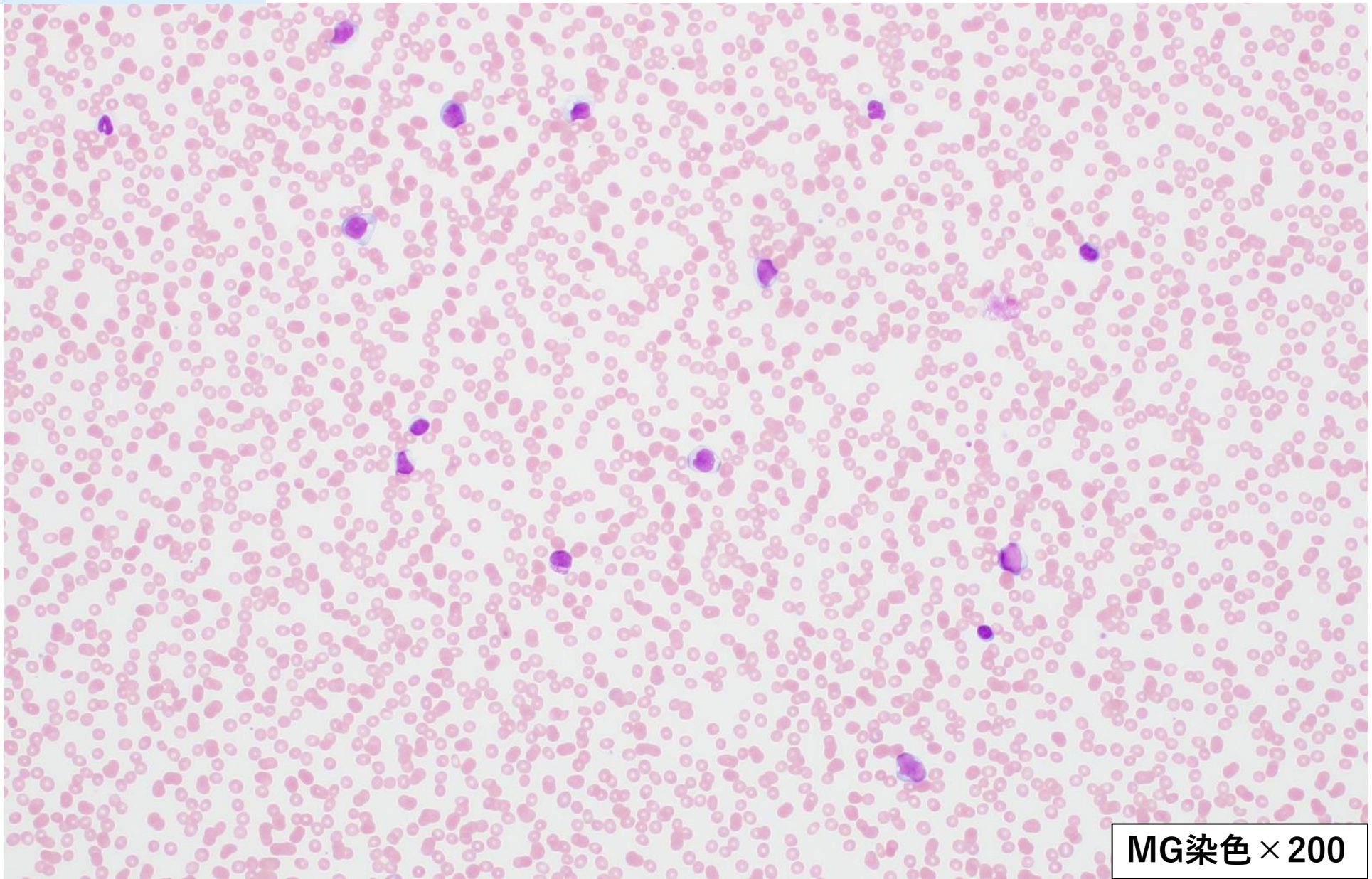

末梢血液像

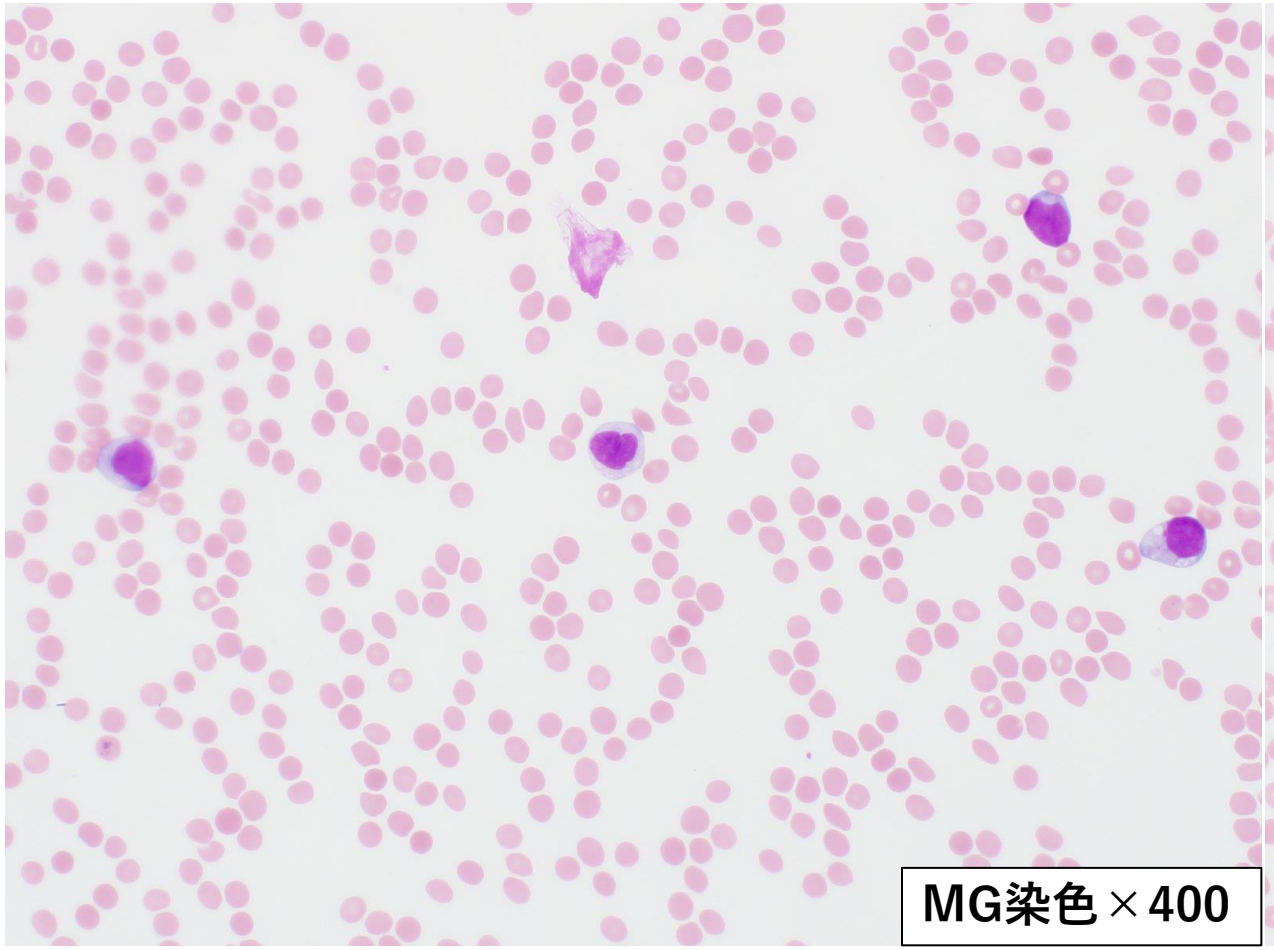

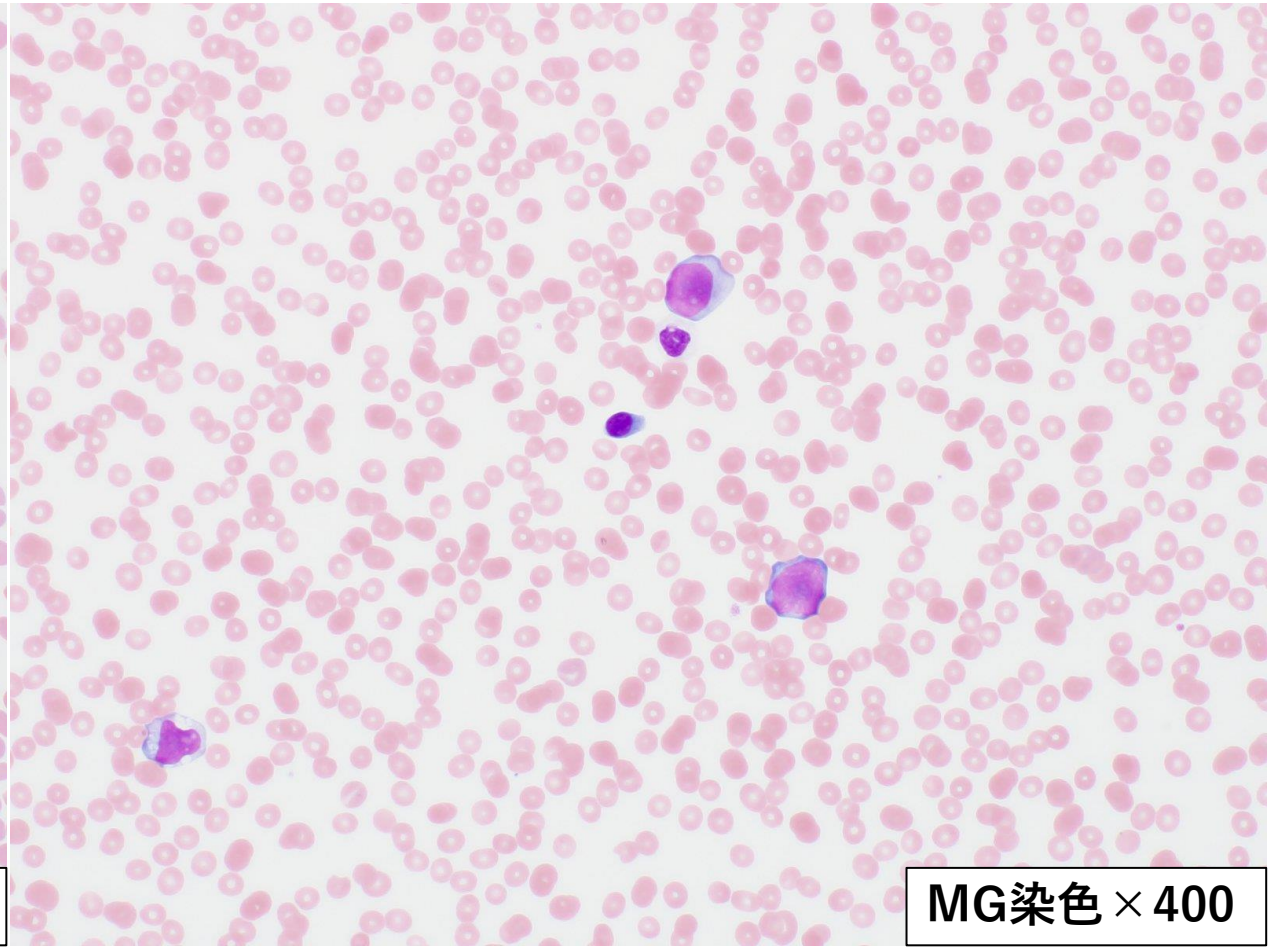

骨髄像

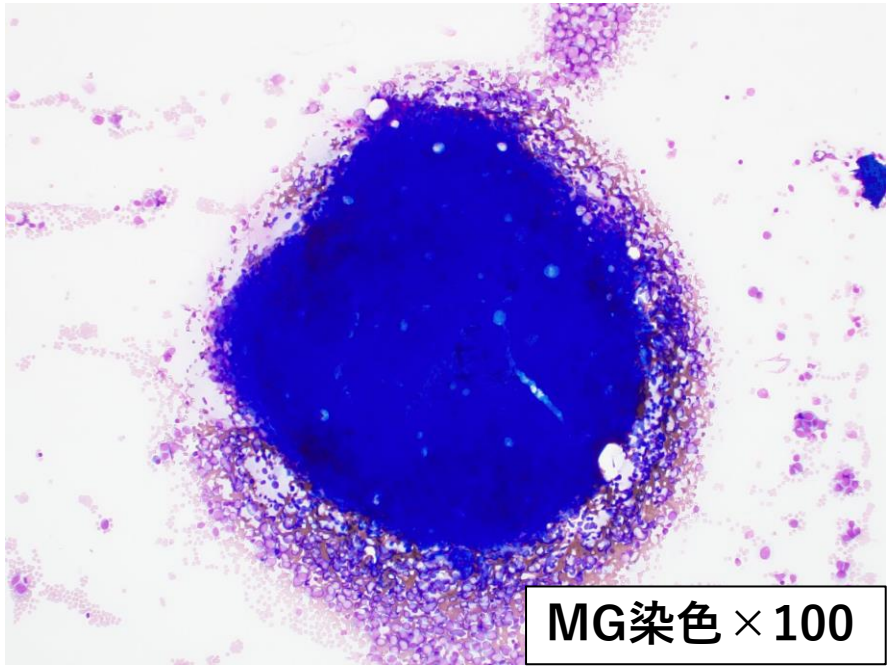

MG染色×100

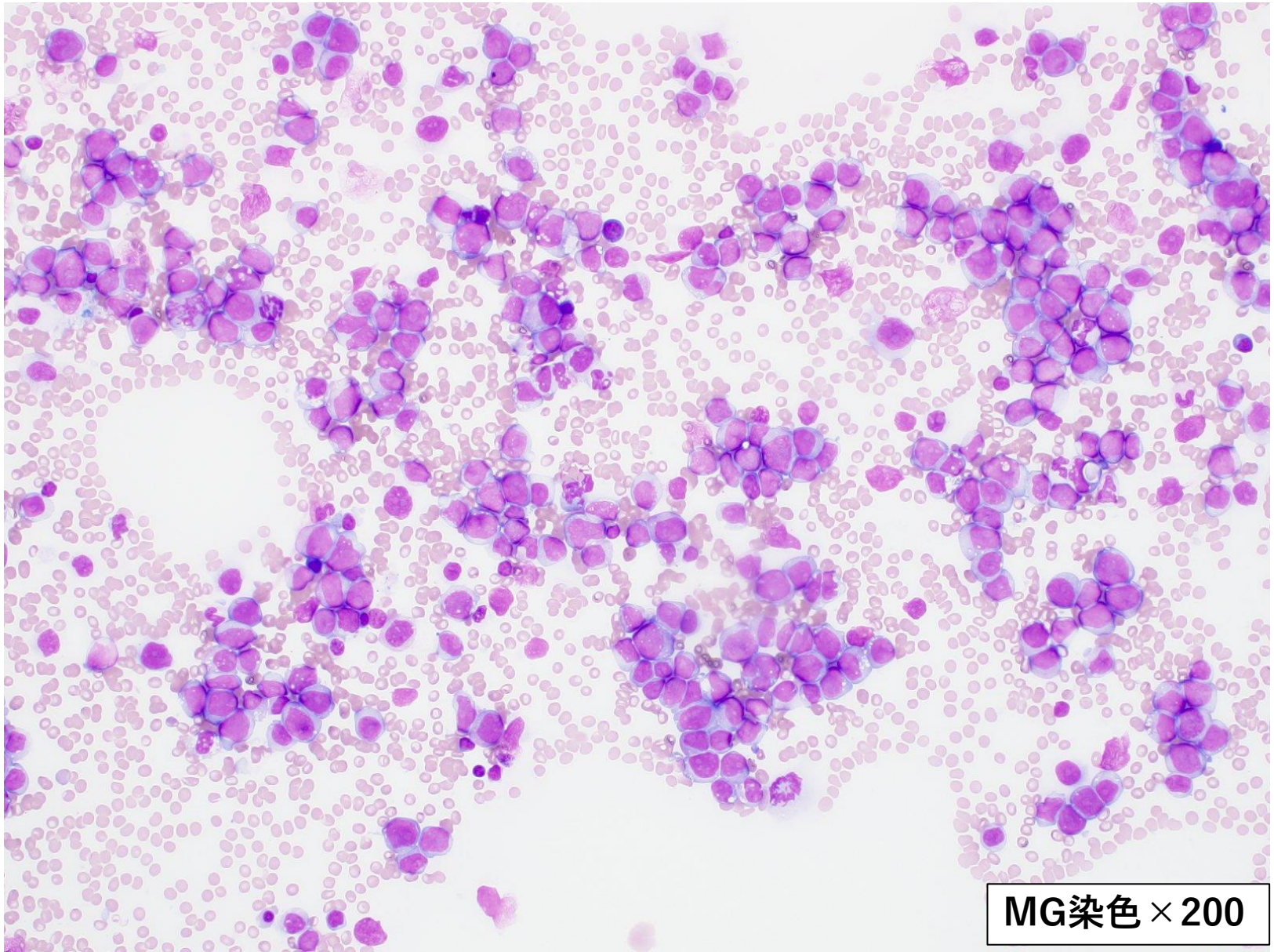

MG染色×200

骨髄像

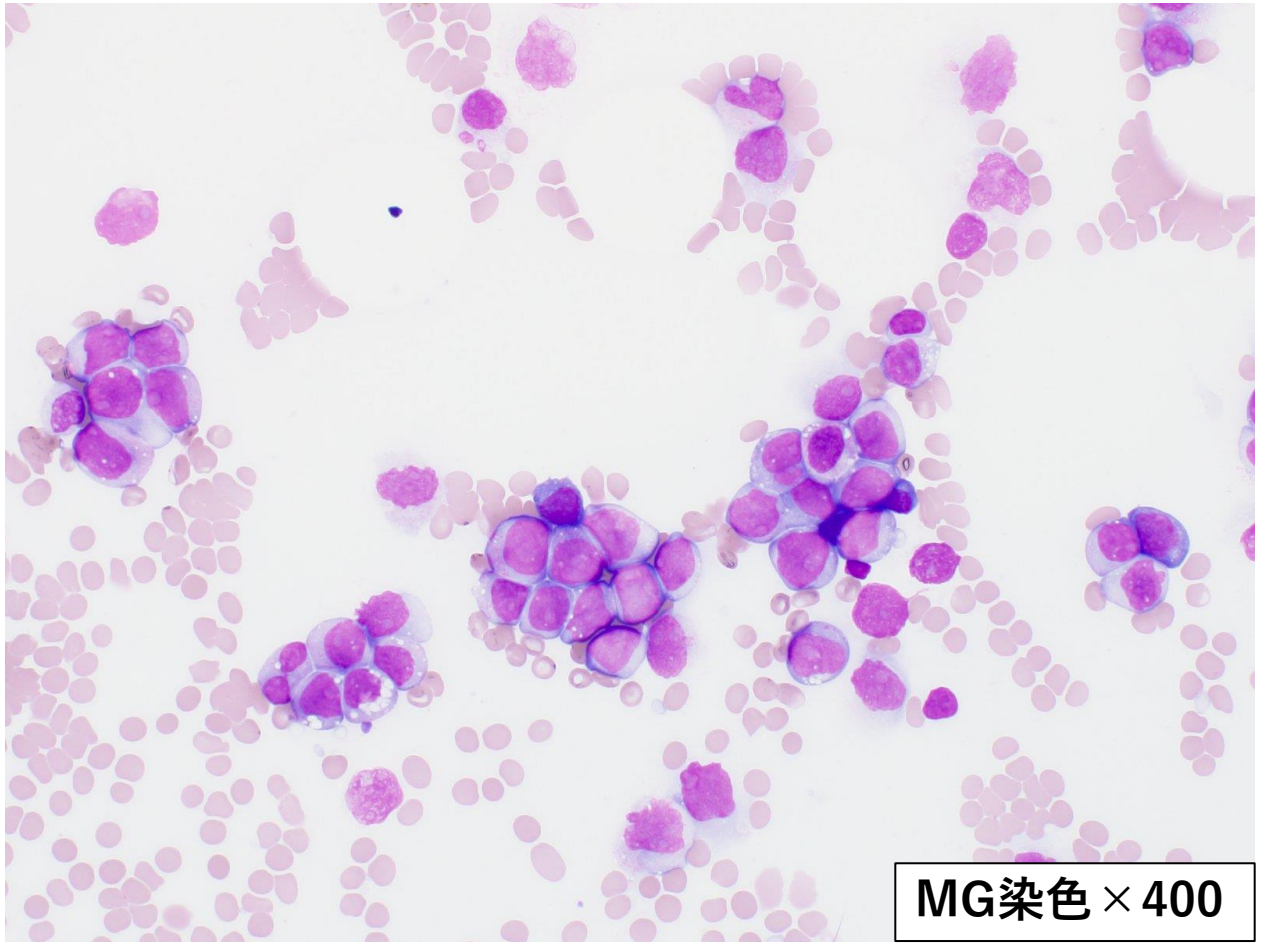

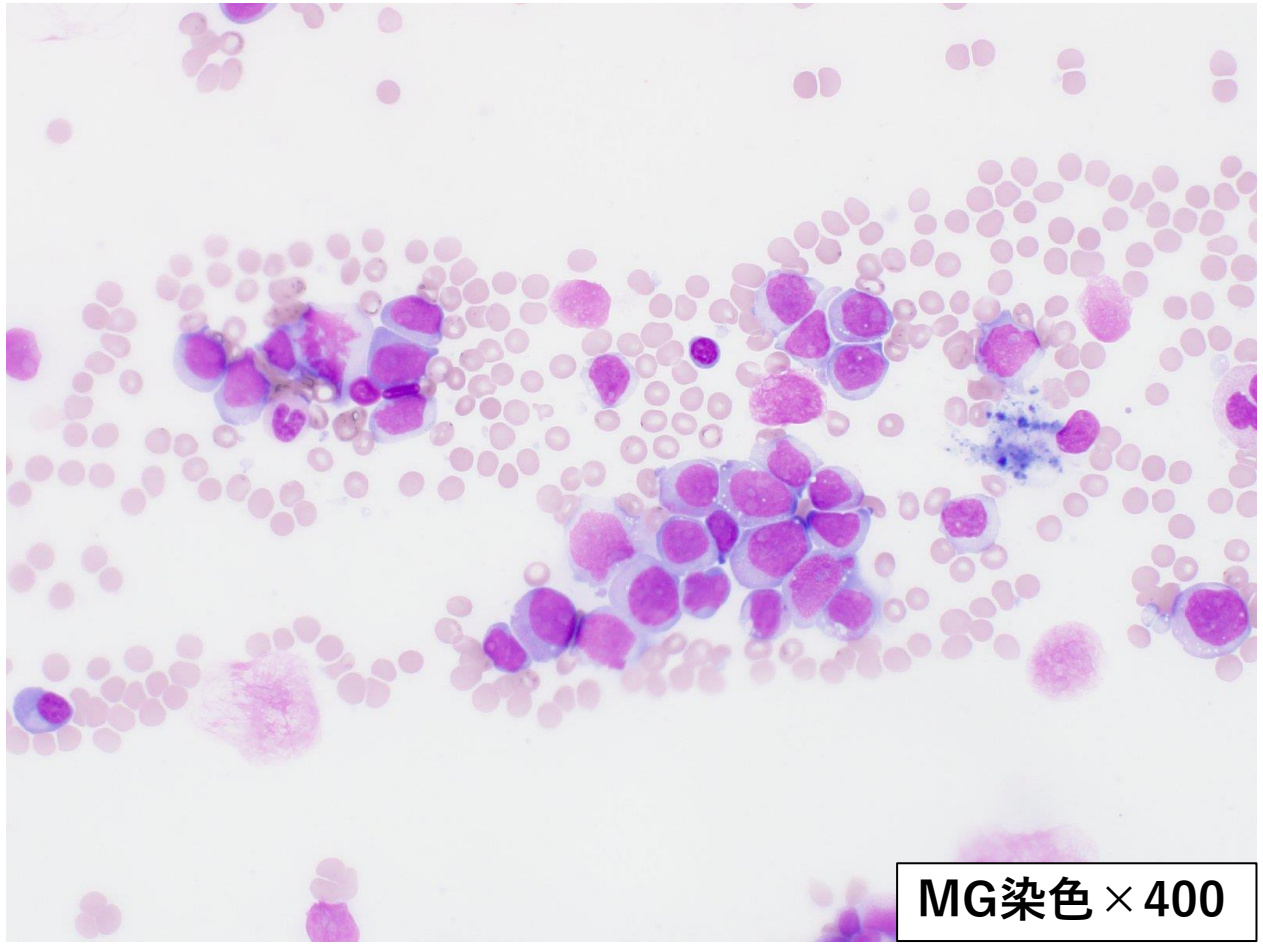

骨髄像

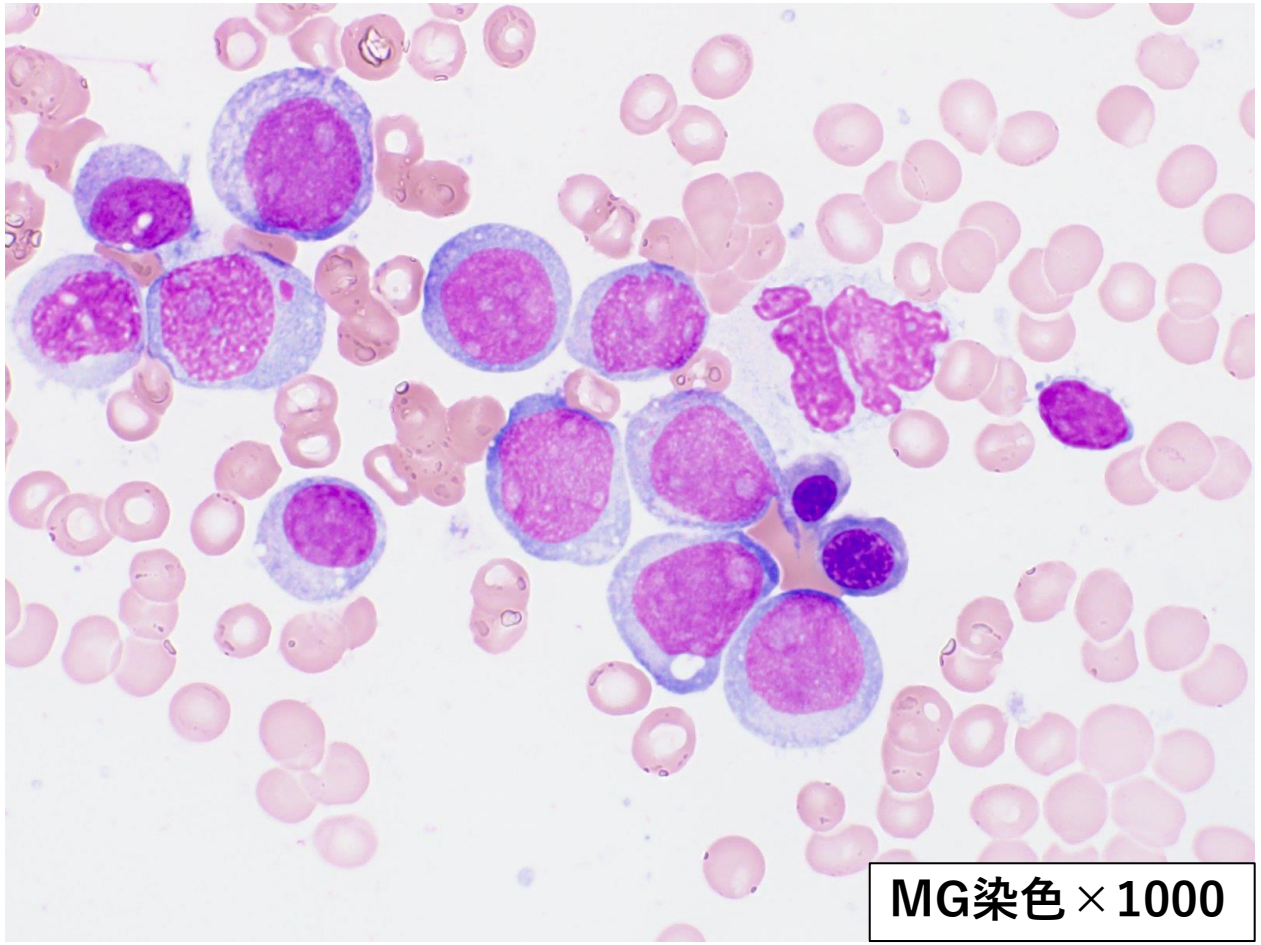

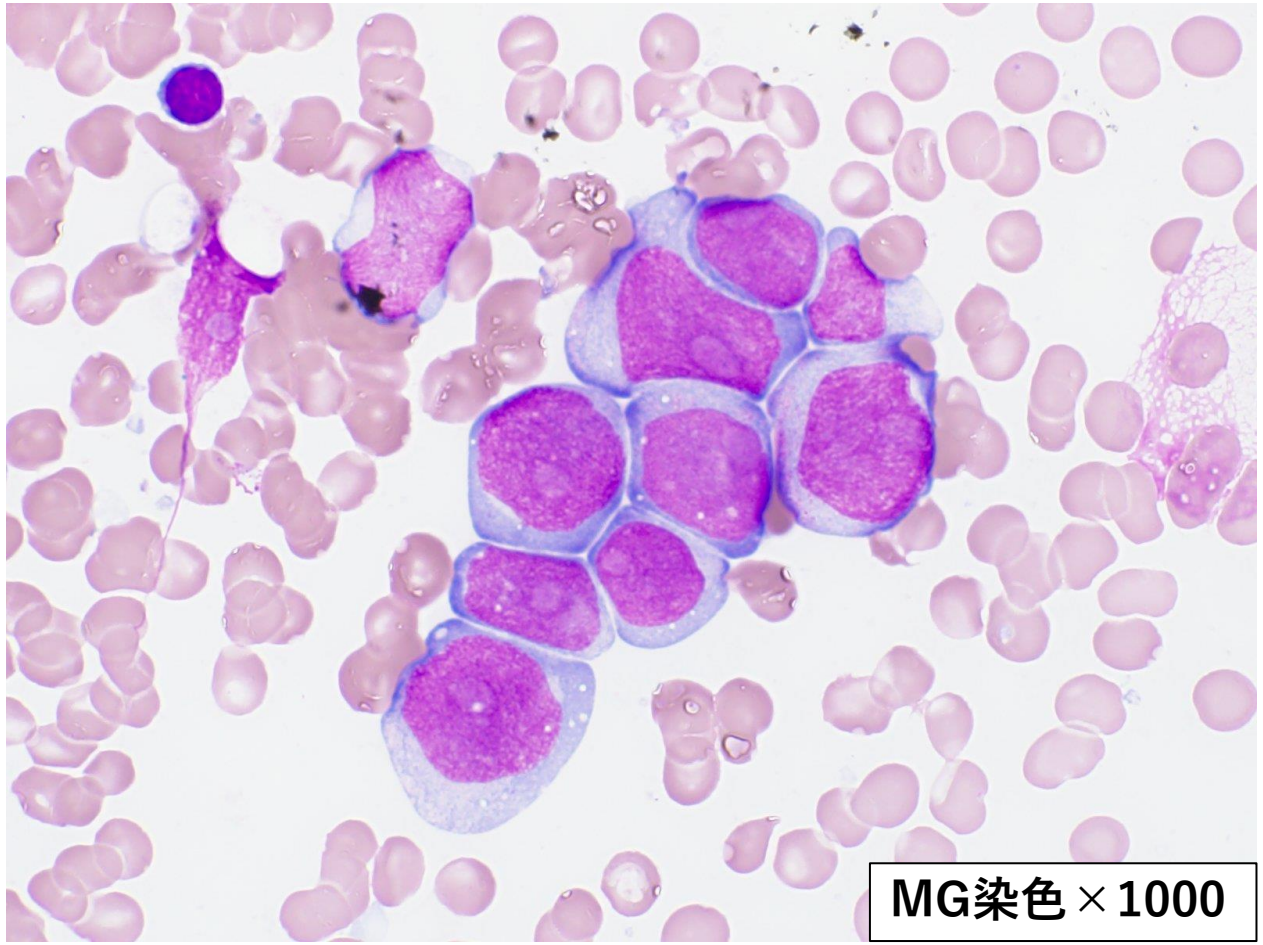

骨髄像

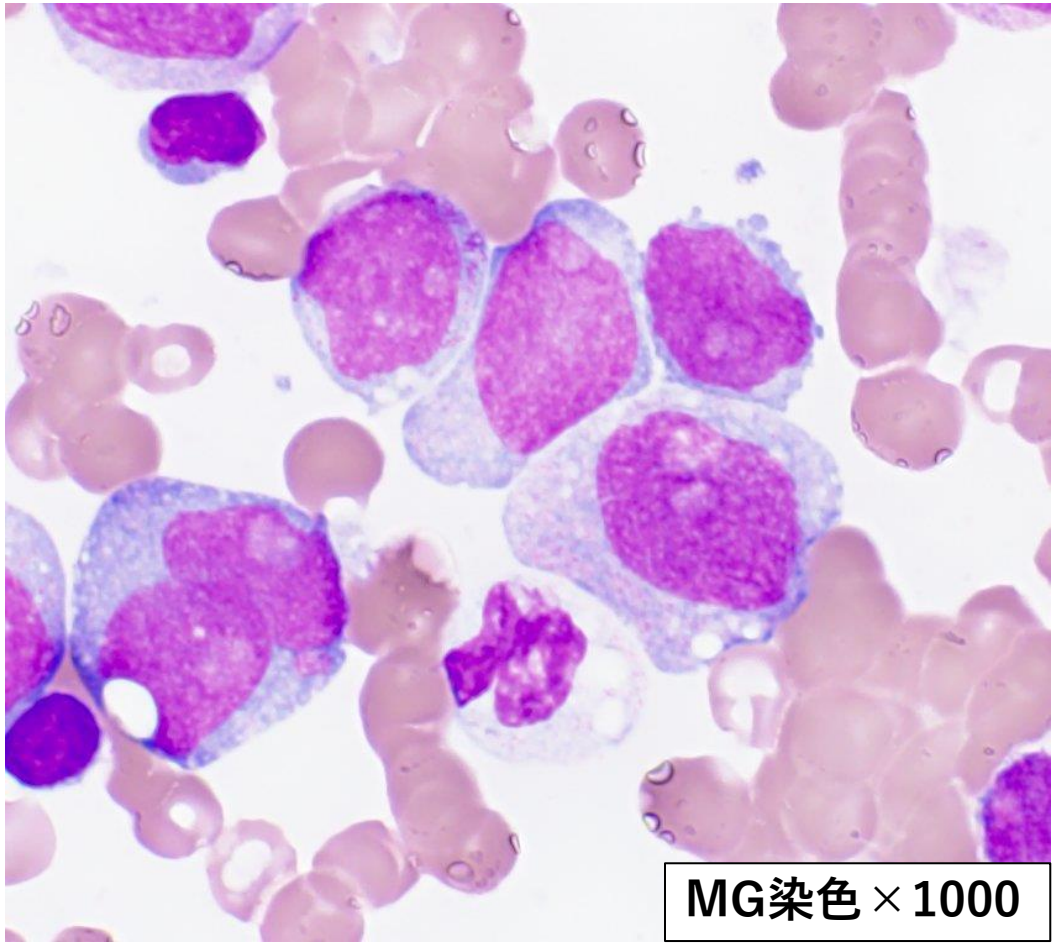

MG染色×1000

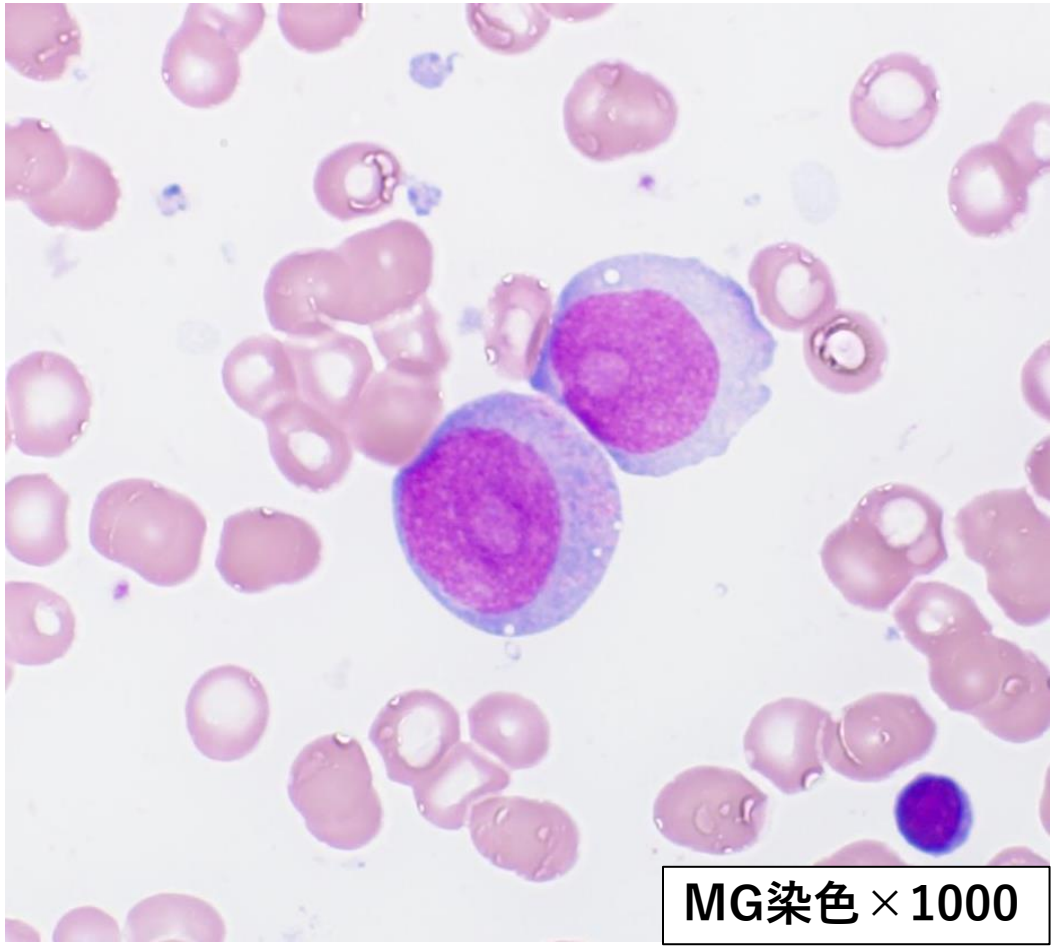

MG染色×1000