症例1

症例

60歳代男性

【主訴】　呼吸苦、動悸、倦怠感

【既往歴】　特になし

【現病歴】

心房粗動、心嚢液貯留認め近医紹介受診。Cardiovarsion施行するも一晩で再燃。心嚢液増多傾向で心嚢ドレナージ施行。
悪性所見なし。
造影CTで右房に造影効果を伴う腫瘤影の指摘あり。

血液検査

TP	5.7 g/dL	ChE	224 U/L
ALB	3.2 g/dL	BUN	8 mg/dL
T-Bil	0.8 mg/dL	CRE	0.88 mg/dL
AST	50 U/L	UA	9.0 mg/dL
ALT	45 U/L	Ca	8.2 mg/dL
ALP	76 U/L	CK	45 U/L
LD	1335 U/L	CRP	1.69 mg/dL

血液検査

		目視カウント					
WBC	5.21 x10^3/μL	Stab	3.0	%		PT-%	73.3 %
RBC	4.35 x10^6/μL	Seg	78.0	%		PT-sec	13.2 sec
Hb	13.0 g/dL	Lym	14.0	%		PT-R	1.16
Ht	39.3 %	Mono	5.0	%		PT-INR	1.17
MCV	90.3 fL	Eo	0.0	%		APTT	48.6 sec
MCH	29.9 pg	Baso	0.0	%		Fib	373.7 mg/dL
MCHC	33.1 g/dL					FDP	4.9 μg/mL
PLT	92 x10^3/μL					DD	2.0 μg/mL
RET%	1.93 %					AT3	94.0 %

末梢血（x200）

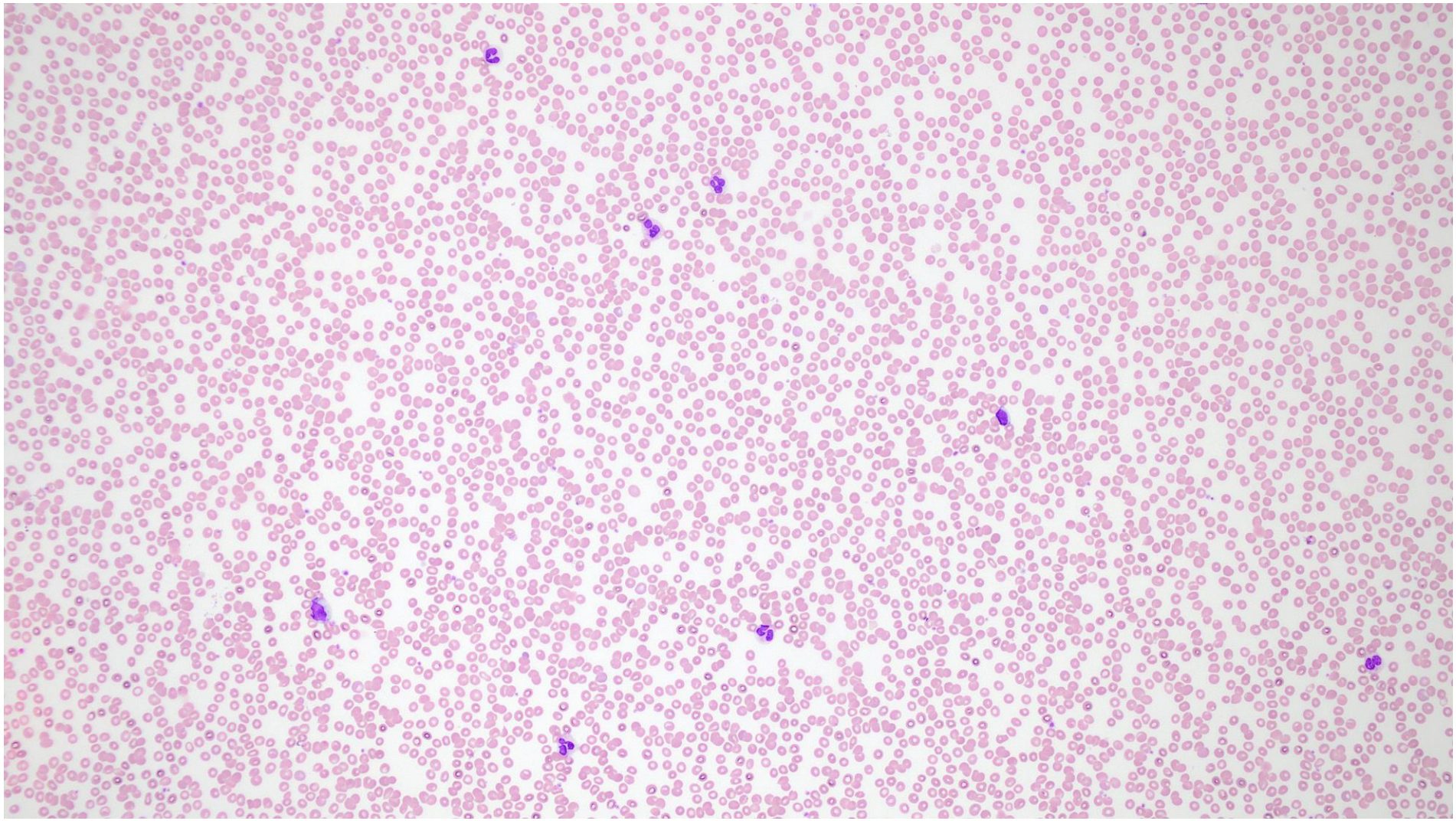

末梢血（x1000）

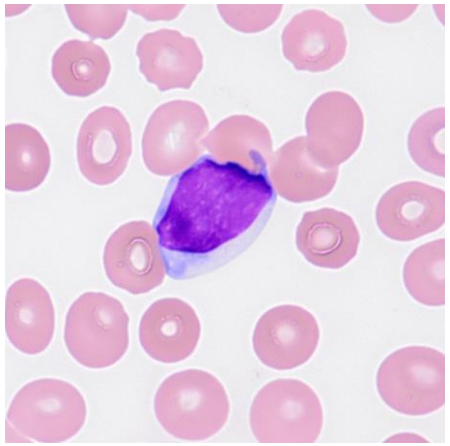

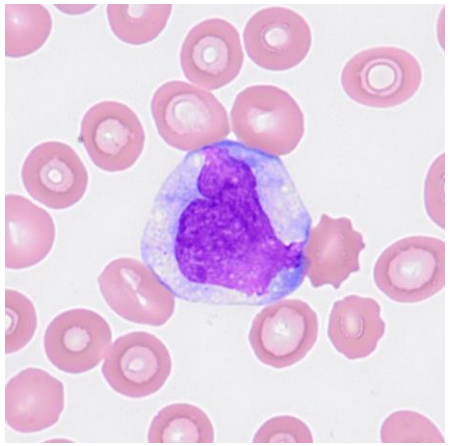

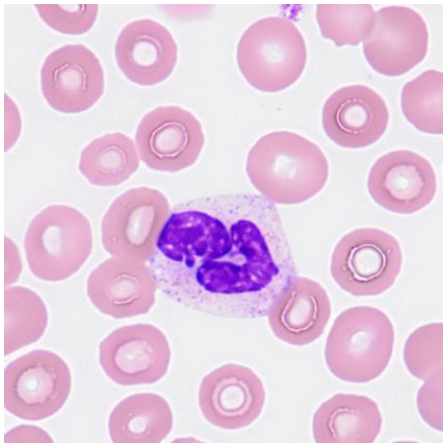

観察に適さない箇所
（カウントには含んでいない）

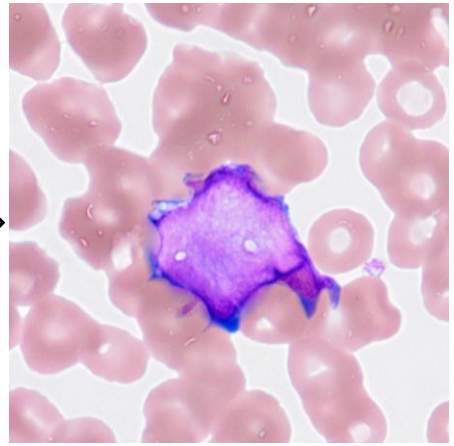

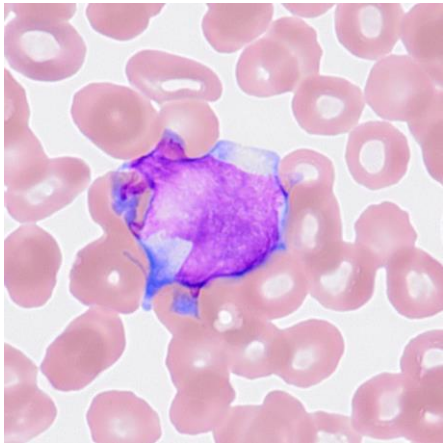

骨髄

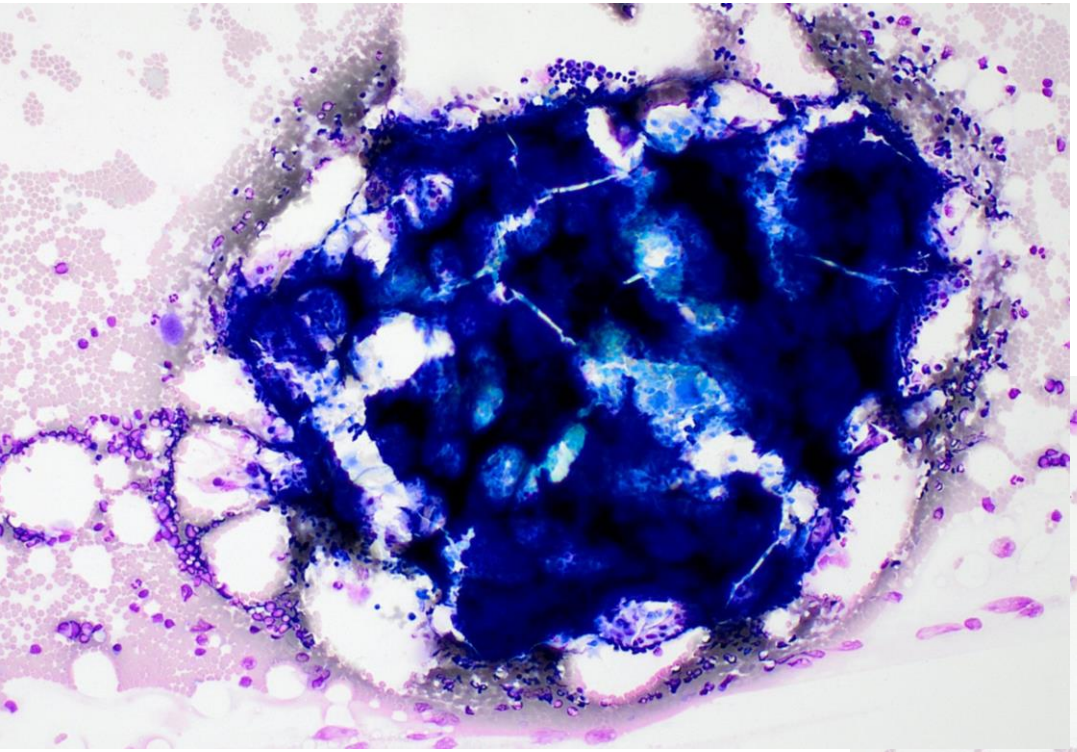

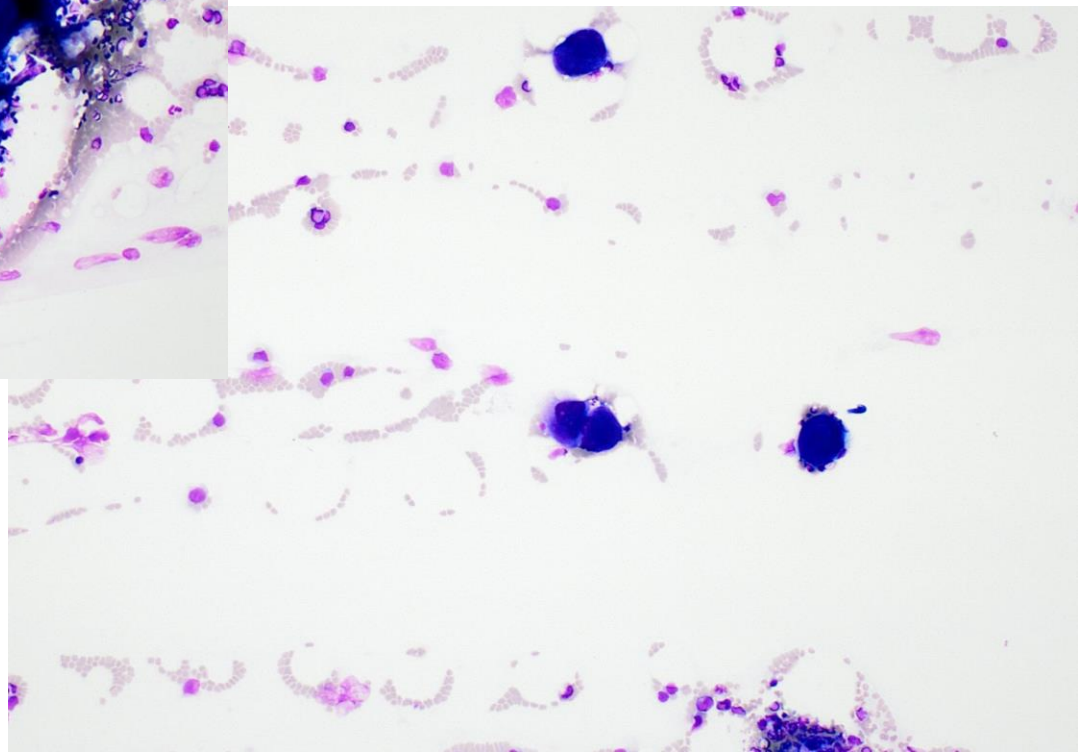

骨髄（x400）

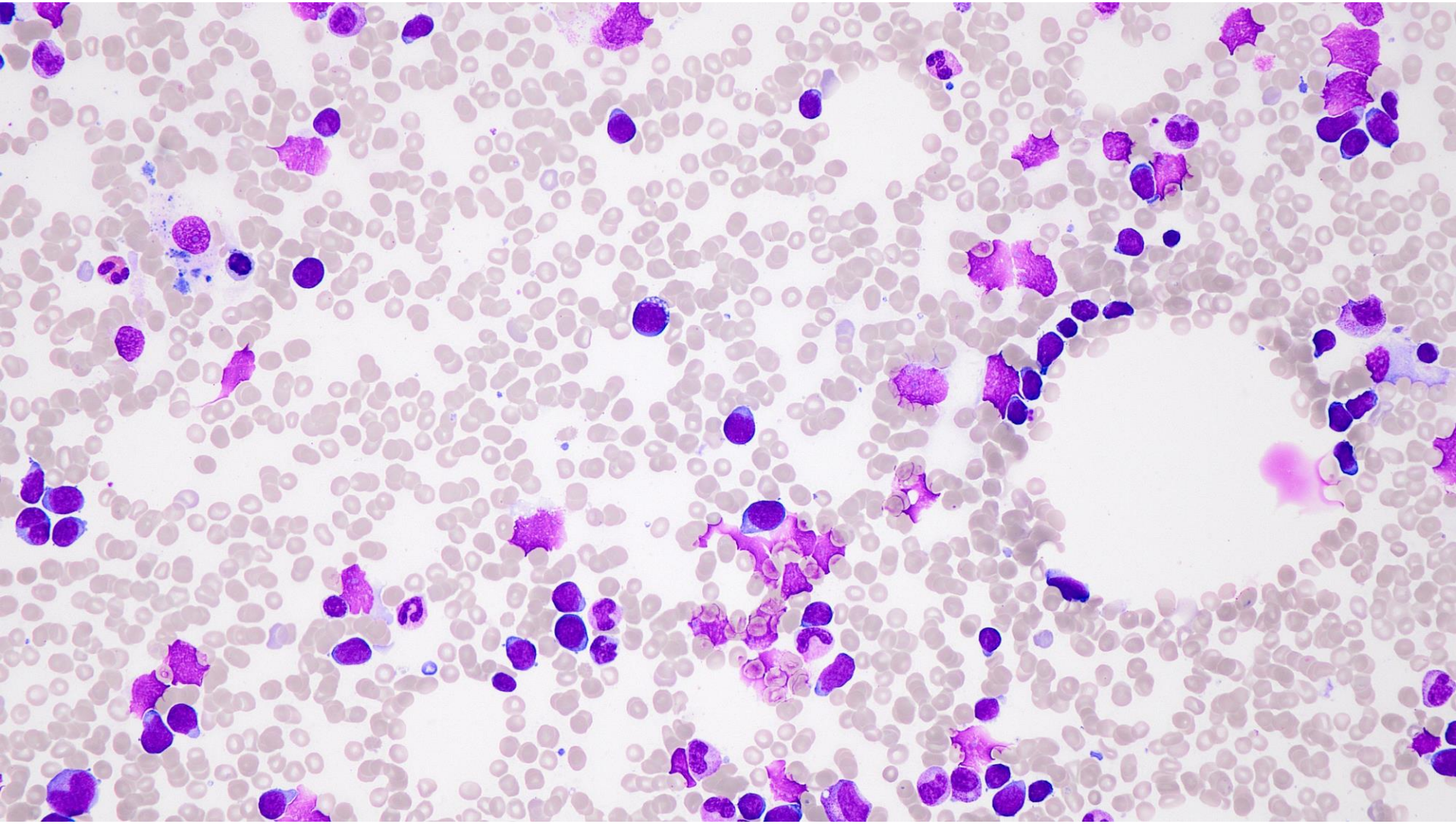
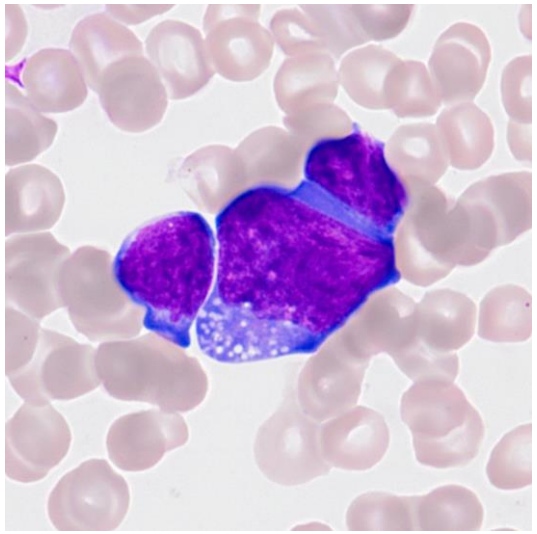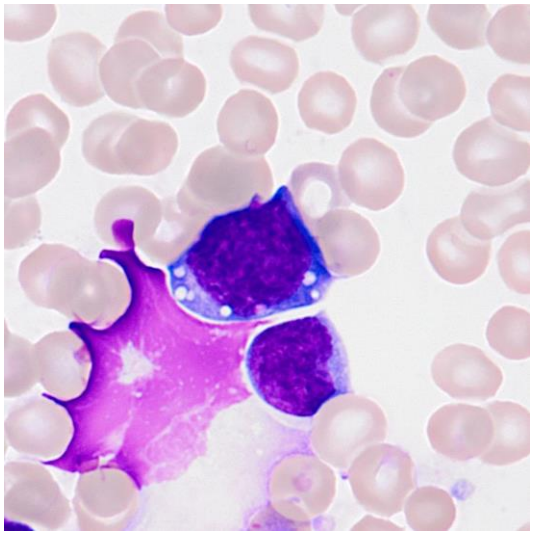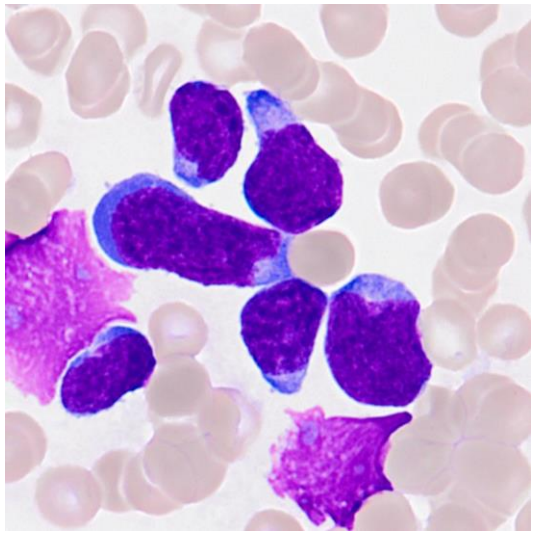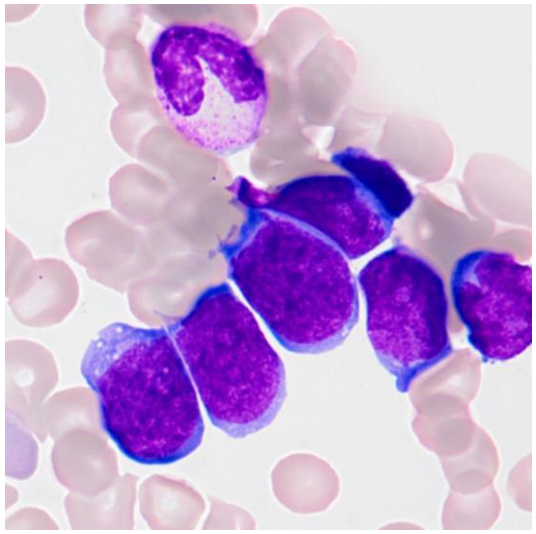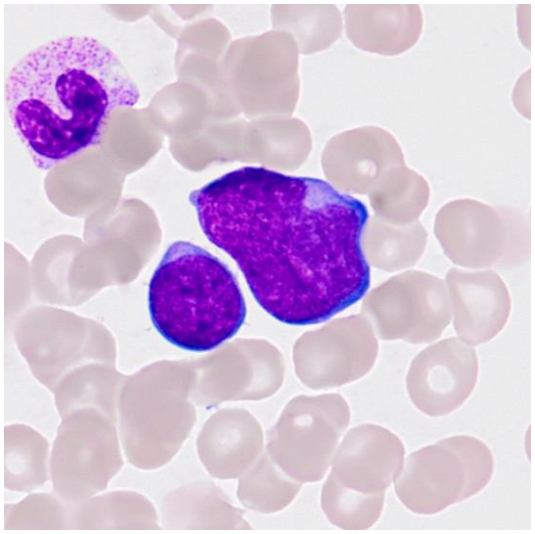
骨髄（x1000）