症例検討会

症例 1

熊本赤十字病院　　龍 正樹

症例1　　60歳代　　女性

- 主訴：40℃の高熱、WBC、Plt、CRP異常高値のため他院から転院搬送
- 既往歴：特になし
- 身体所見：胸部X線にて、肺野全体にすりガラス影や浸潤影あり
  CTにて、著明な脾腫を認める

症例1 検査所見

血液学的検査		
WBC	56.8	$\times 10^9$/L
RBC	3.05	$\times 10^{12}$/L
Hb	8.8	g/dL
Hct	27.3	%
MCV	89.6	fL
MCH	28.9	pg
MCHC	32.3	g/dL
PLT	1710	$\times 10^9$/ L

生化学検査		
TP	4.9	g/dL
ALB	2.0	g/dL
LD	699	U/L
AST	25	U/L
ALT	21	U/L
ALP	122	U/L
T-Bil	0.3	mg/dL
BUN	31.0	mg/dL
Cre	0.89	mg/dL
CRP	40.0	mg/dL

凝固検査		
PT (秒)	13.7	秒
PT (%)	69	%
PT (INR)	1.21	
APTT	52.7	秒

末梢血液像

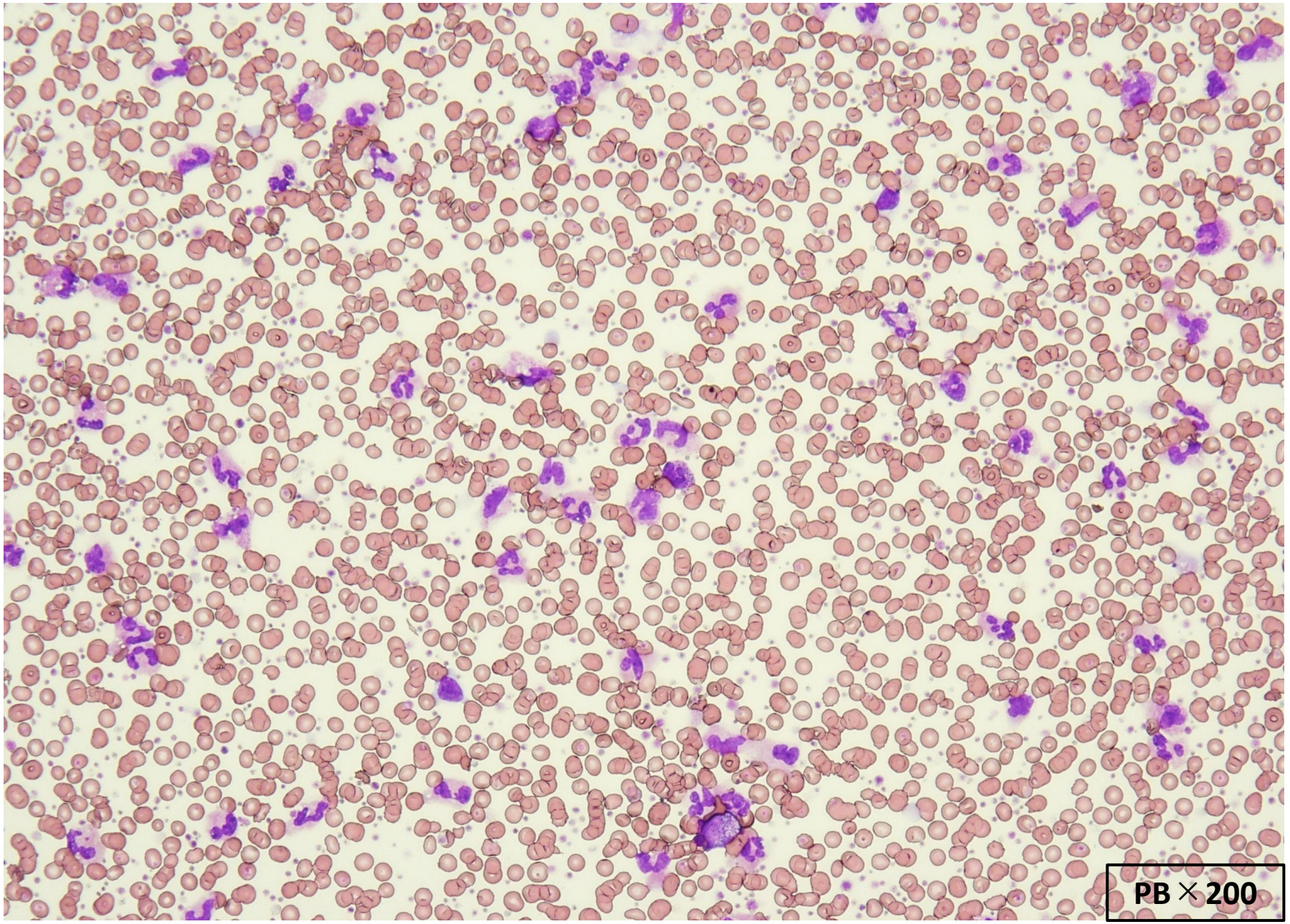

白血球百分比	
Blast	2.0 %
Pro	1.5 %
Myelo	1.5 %
Meta	3.0 %
Stab	12.5 %
Seg	74.5 %
Lymph	2.0 %
Mono	0.5 %
Eosino	0.5 %
Baso	2.0 %

末梢血液像

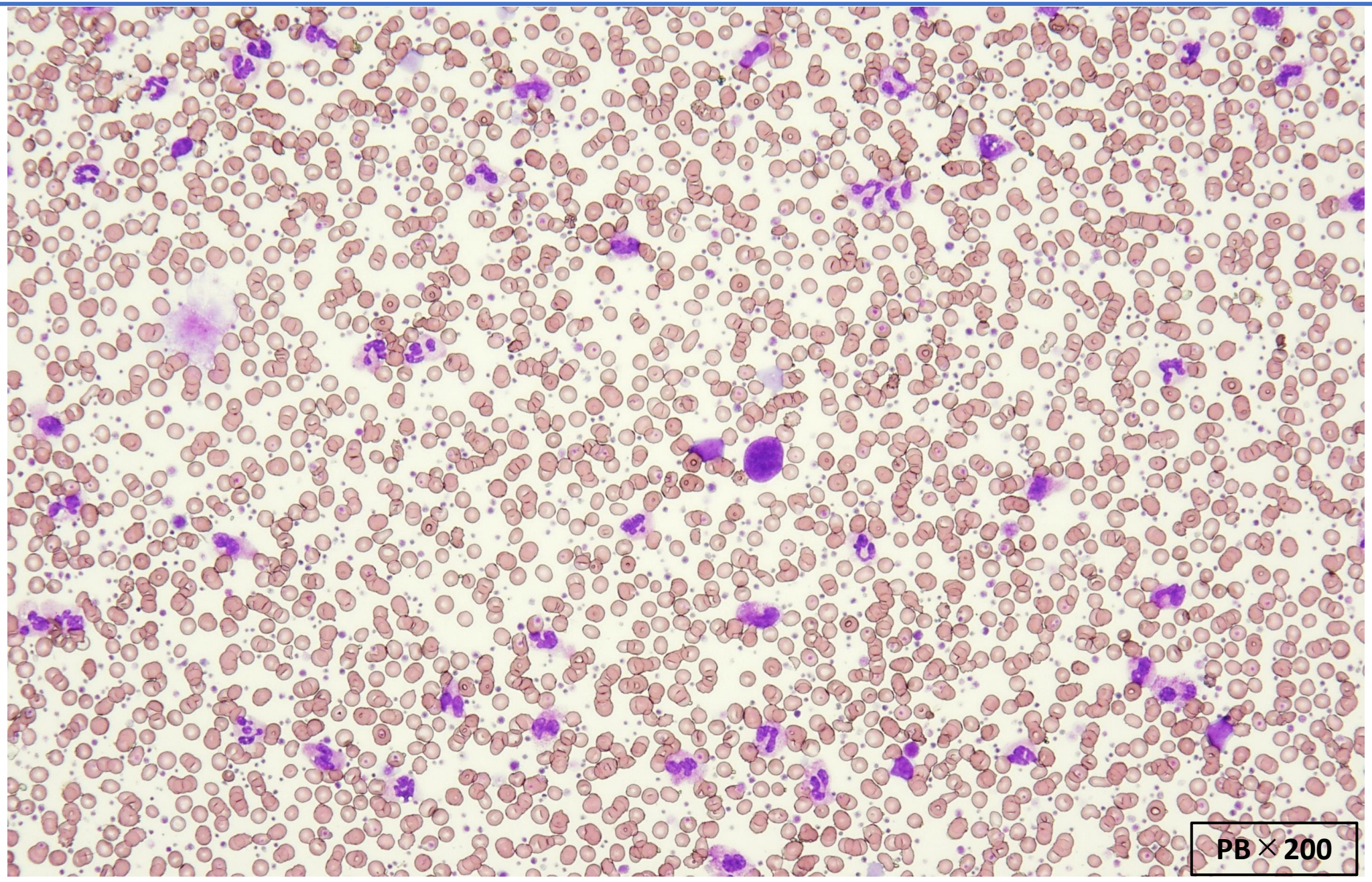

末梢血液像

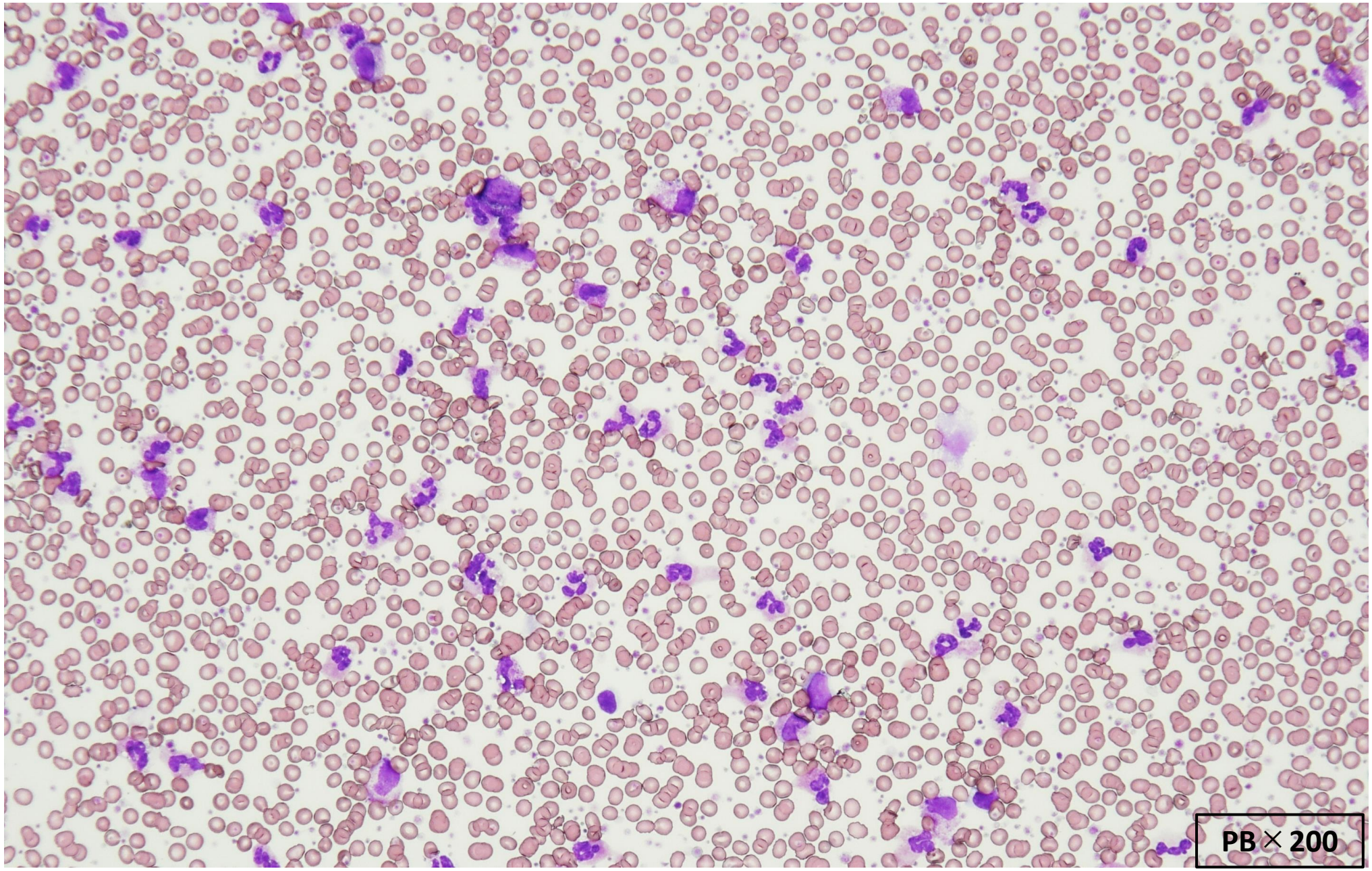

末梢血液像

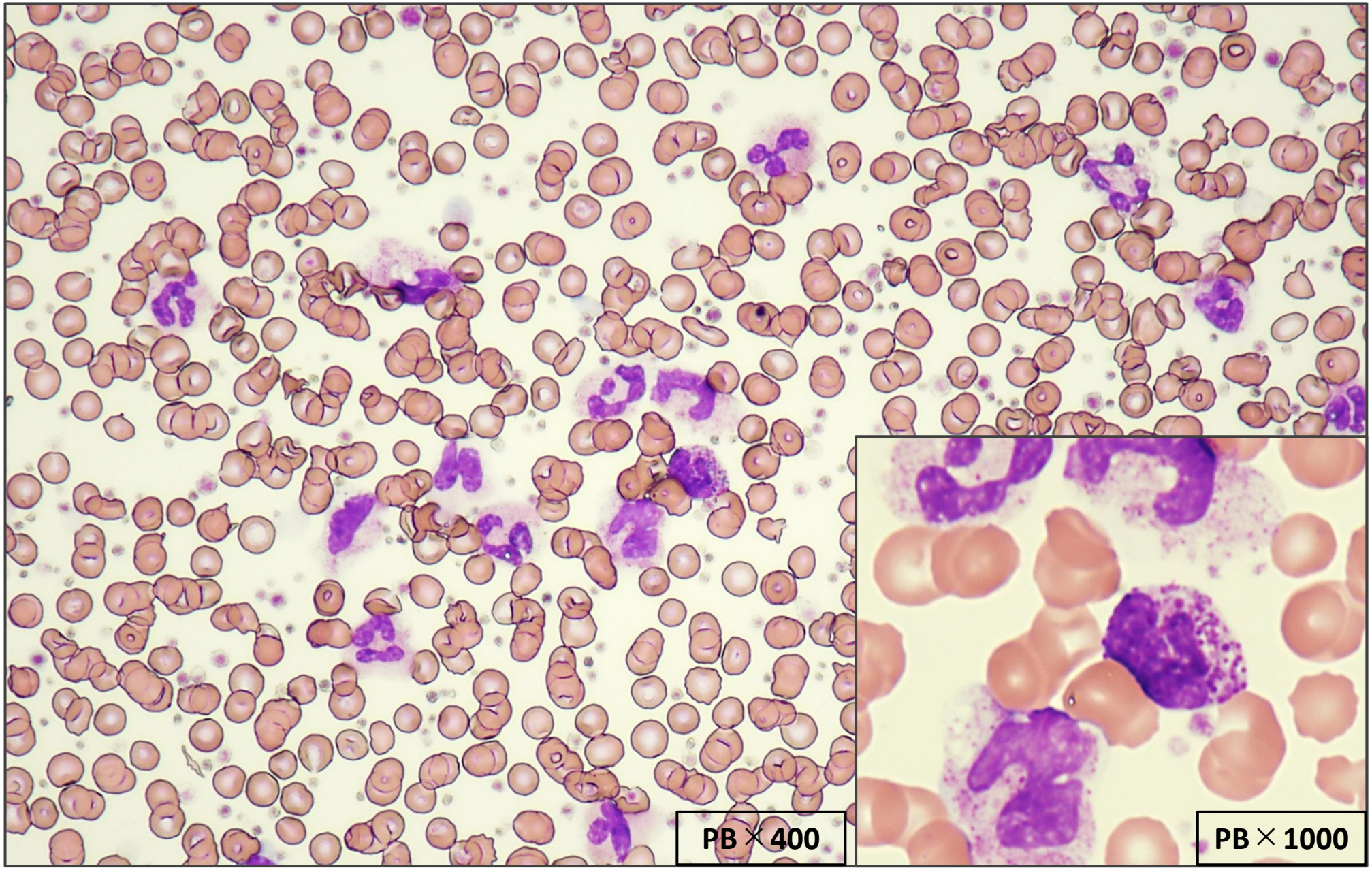

末梢血液像

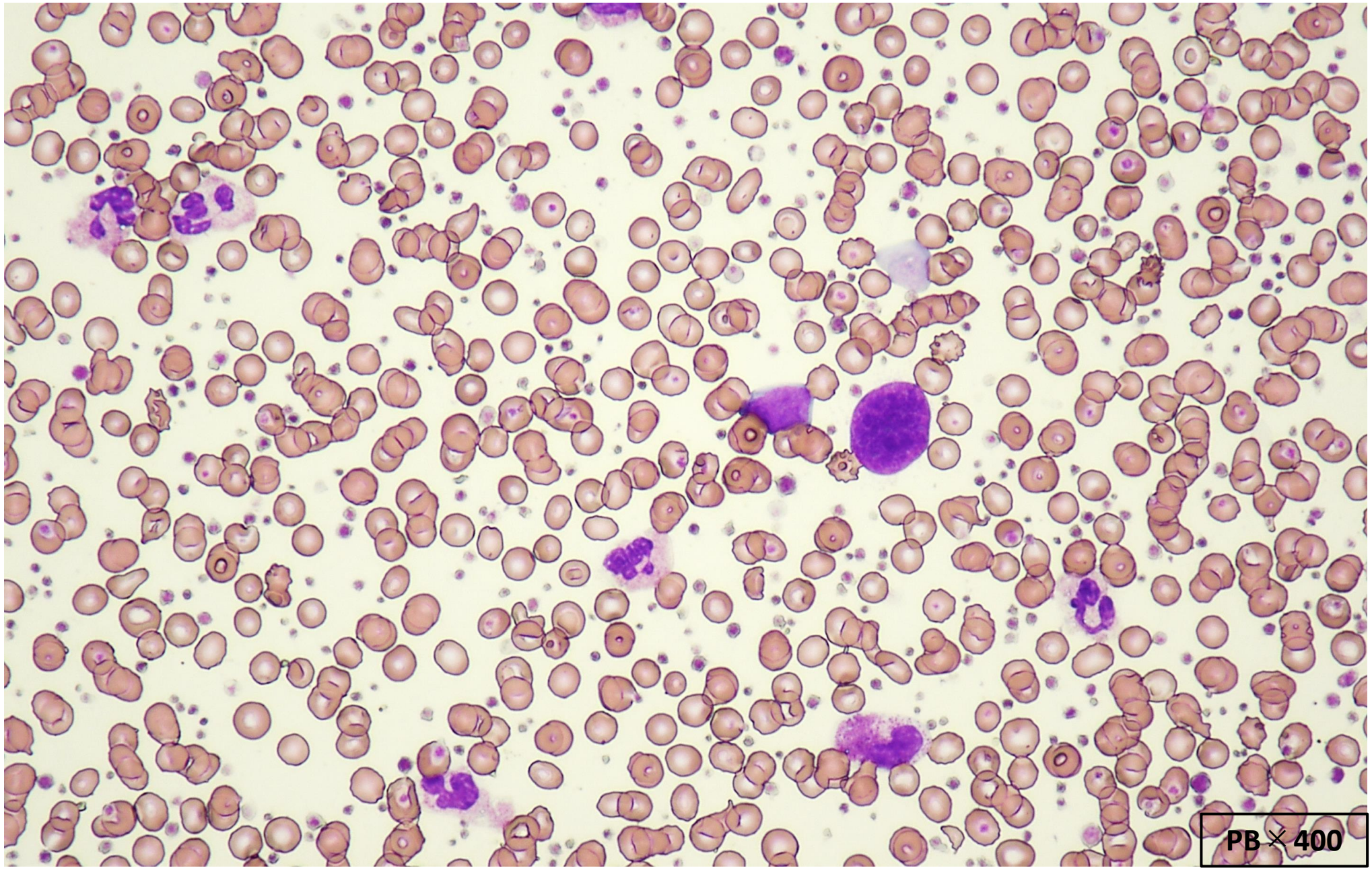

末梢血液像

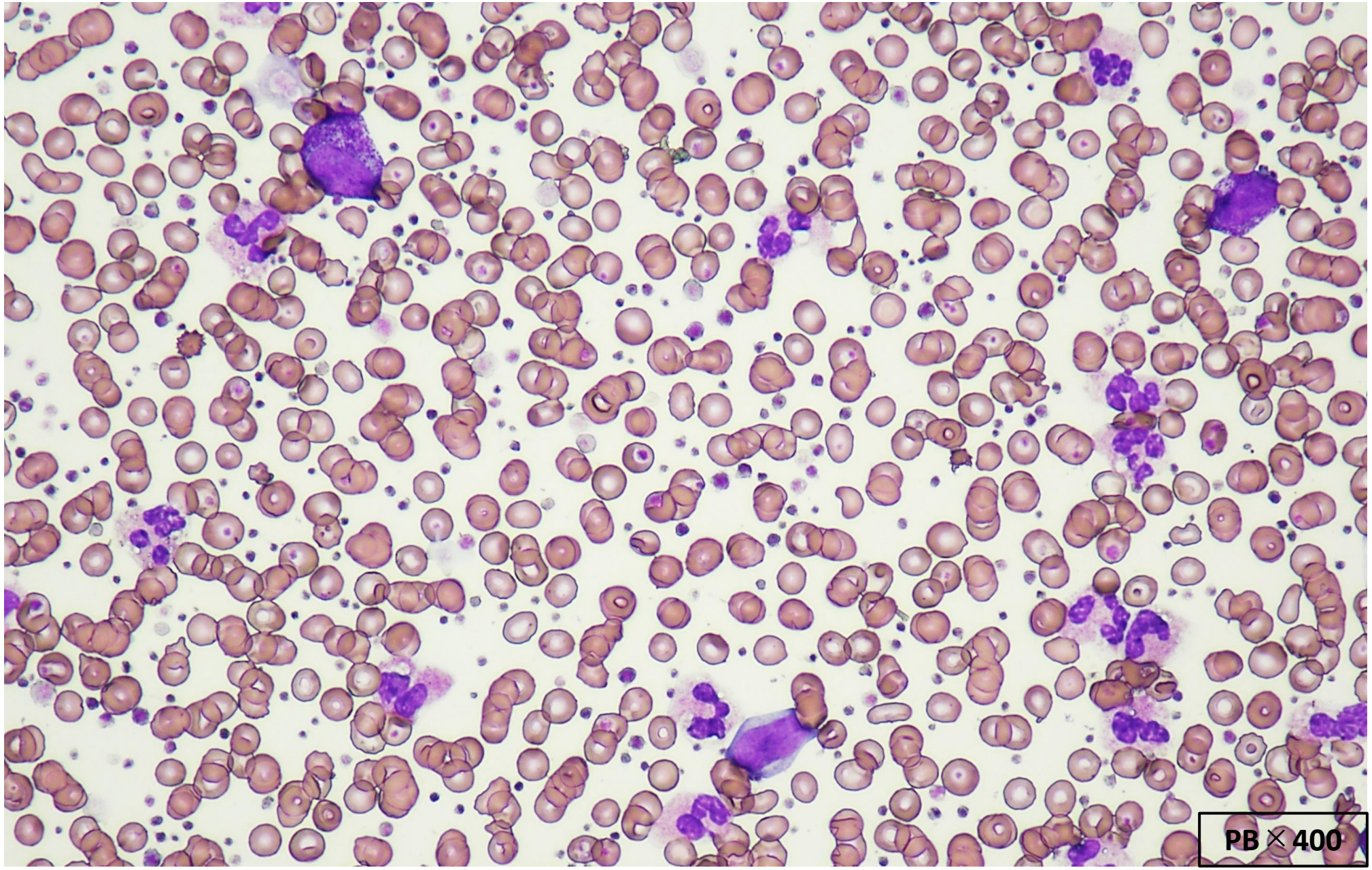

末梢血液像(ALP染色)

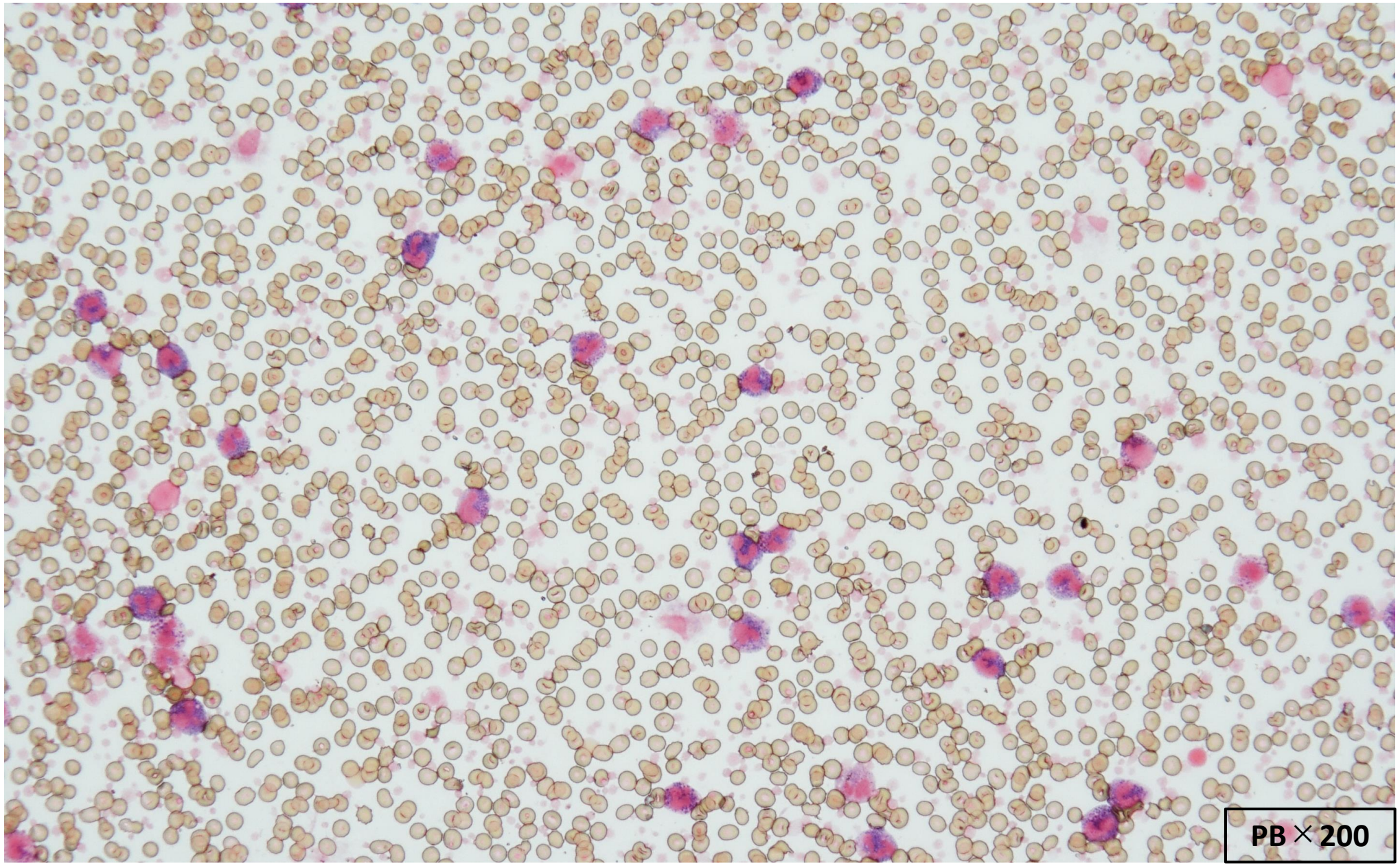
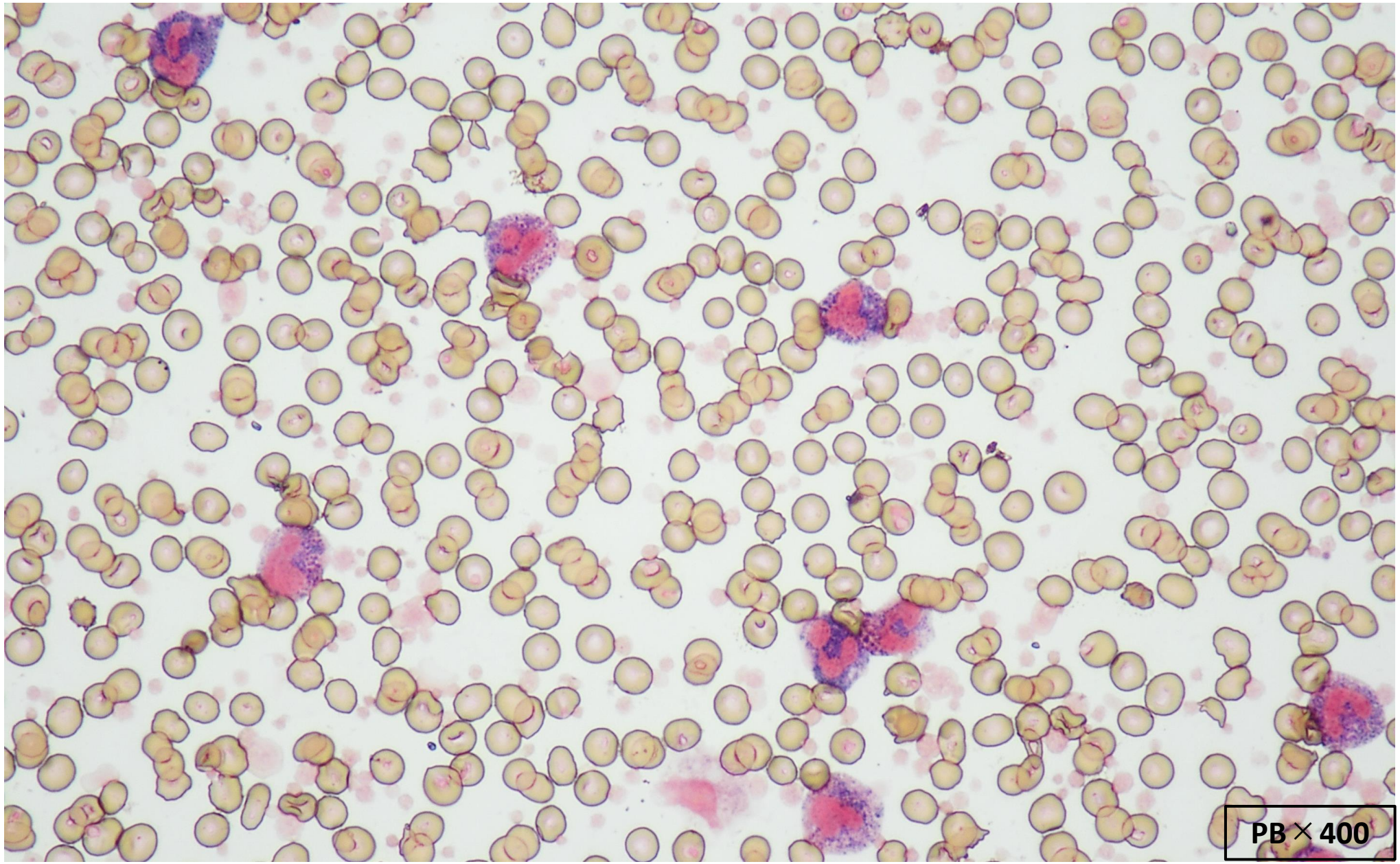
末梢血液像(ALP染色)